



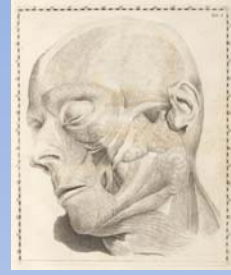Santorini, D. 1775

Anatomic Study of Sub-Platysmal Fat

An D. Lu and Joel E. Pessa, M.D.

Eastfield Community College, Mesquite, TX;

Department of Plastic Surgery, UT Southwestern Medical Center, Dallas, TX;



Santorini, D. 1775

Abstract

- **Background:** Examination of a cross section of the head showed regional differences in sub-platysmal fat, suggesting there are separate fat compartments.
- **Methods:** 5 cervical cadaver dissections were performed in the anatomy lab. Dye was injected to confirm the compartments in two specimens.
- **Result:** There are different sub-platysmal fat compartments separated by anatomical boundaries.
- **Conclusion:** A better understanding of the sub-platysmal fat compartments will lead to improved results in plastic surgery.

Background

- Subcutaneous fat of the face has been described to exist in different compartments.¹
- In plastic surgery, removing only the central sub-platysmal fat in people with heavy necks results in a hollow area under the chin.
- Observations suggest there are different fat compartments under the platysma muscle.

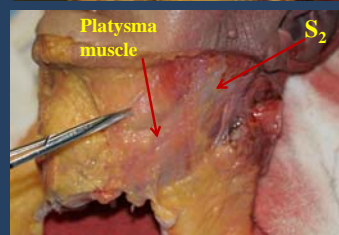
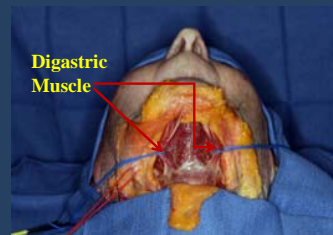
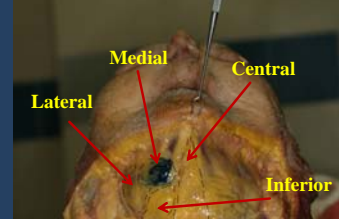
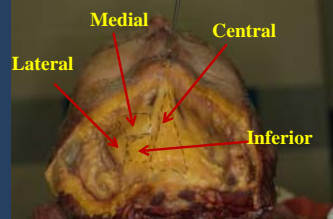
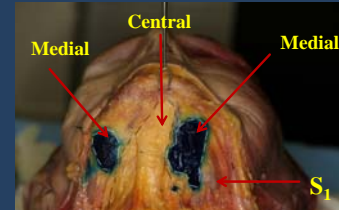
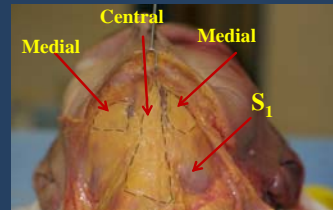
Methodology

- The study of the sub-platysmal fat compartment was performed in the anatomy lab by dissecting the necks of 2 female and 3 male fresh cadavers ranging in age from 66 to 88 years.
- Methylene blue was injected into the sub-platysmal fat after the skin, supra-platysmal fat and the platysma were elevated and was allowed to diffuse for 12 hours, although the result could be seen immediately. Glue was used to prevent the dye from leaking through the surface.

S₁-submandibular gland

S₂- Sternocleidomastoid muscle

Results



- The sub-platysmal fat is divided into central, medial, lateral and inferior compartments with anatomical boundaries.
- The central compartment lies between the digastric muscles.
- The medial compartment lies between the anterior digastric muscle and the submandibular gland.
- The lateral compartment lies above the submandibular gland and is bounded by the sternocleidomastoid muscle.
- The inferior compartment requires further dissection to identify its anatomical boundaries.

Conclusion

- The sub-platysmal fat of the neck is divided into separate compartments.
- The central, medial and lateral compartment are separated by anatomical boundaries; further dissection is required to identify the inferior compartment's boundaries.
- Better understanding of this anatomy will lead to improved results in plastic surgery.

Future Implications

- Scientific research can be done to evaluate the role of genes in fat compartments.
- Further research might show how genetics and fat differences affect obesity, diabetes, and heart disease.

Functions

- The fat improves gliding between the muscles.
- The platysma muscle might depresses the lower lip.
- The sternocleidomastoid muscle mainly flexes the neck.
- The digastric muscles open the jaw.
- The submandibular gland secretes saliva.

Acknowledgements

- Kind thanks to Dr. Rohrich, Dr. Thornton and Dr. Saint-Cyr from the Department of Plastic Surgery for the generosity.
- The Willed Body Program and the Anatomy Lab at UT Southwestern Medical Center.
- STARS Program
 - Dr. Ravnik
 - Lynn Tam
- Eastfield College
- National Science Foundation Grant # DUE-052536

Reference

1. Rohrich RJ, Pessa JE. The fat compartment of the Face: Anatomy and Clinical Implications for Cosmetics Surgery. Volume 119 (7), June 2007, pp 2219-2227. Department of Plastic Surgery, UT Southwestern Medical Center.